

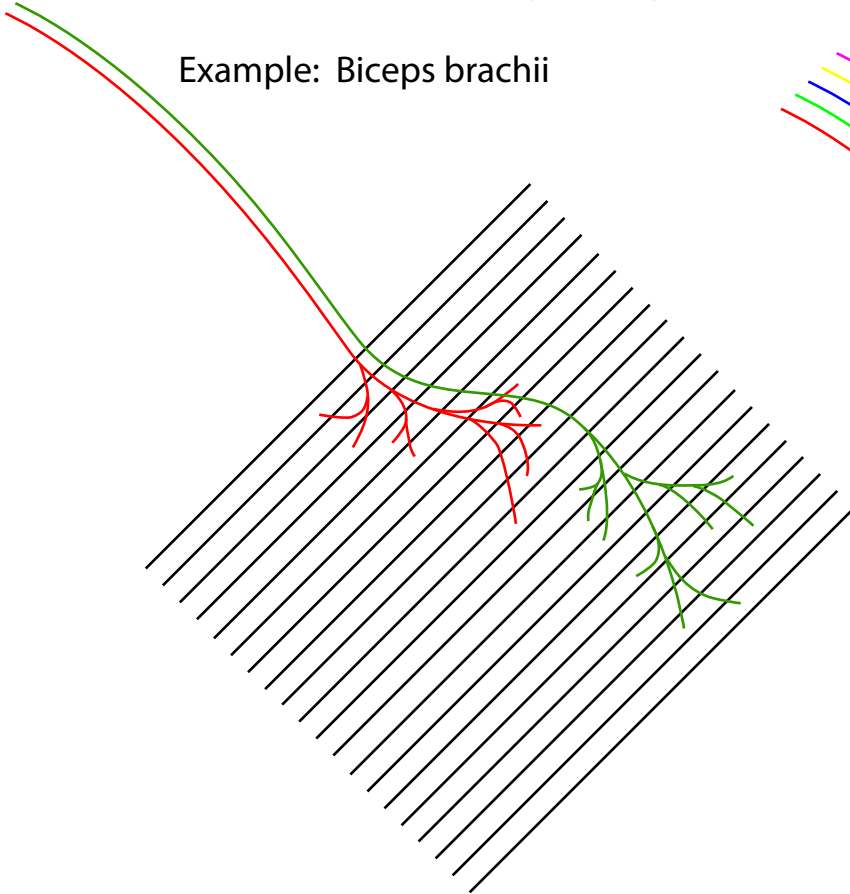
# *Innervation of Skeletal Muscle Tissue*

## *Gross Motor Movements:*

- Few motor units
- Each motor unit is large

Therefore, nerves servicing muscles of gross motor movements are *relatively* small, even though the muscle may be very large.

Example: Biceps brachii



## *Fine Motor Control:*

- Many motor units
- Each motor unit is small

Therefore, nerves servicing muscles of fine motor control are *relatively* large, even though the muscle may be small.

Examples: Muscles that control eye movement or the tongue.

